REFERENCES

1. Van Herle AJ, Chopra IJ
Thymic hyperplasia in Grave's disease
J. Clin. Endocrinol. Metab. 1971; 32: 140-6

2. Wortsman J, McConnachie P, Baker JR, Burman KD
Immunoglobulins that cause thymocyte proliferation from a patient with Grave's disease and an enlarged thymus
Am. J. Med. 1988; 85: 117-21

3. Murakami M, Hosoi Y, Negishi T *et al.*
Thymic Hyperplasia in Patients with Grave's Disease
J. Clin. Invest. 1996 98: 2228-34

4. Budavari AI, Whitaker MD, Helmers RA
Thymic hyperplasia presenting as anterior mediastinal mass in two patients with Grave's disease
Mayo. Clin. Proc. 2002; 77: 495-9

5. Xu PX, Zheng W, Laclef C, Maire P, Maas RL, Peters H, Xu X
Eya1 is required for the morphogenesis of mammalian thymus, parathyroid and thyroid
Development 2002; 129: 3033-44

GRAVE'S DISEASE

- is named after Irish physician Robert Grave (1796-1853)
- is the most common cause of hyperthyroidism
- is caused by autoantibodies and over-stimulation of the thyroid gland
- is 10 times more common in females
- may be associated with other autoimmune conditions, *e.g.* Type 1 diabetes mellitus, pernicious anaemia and vitiligo
- symptoms of hyperthyroidism include weight loss, increased appetite, heat intolerance, diarrhoea, oligomenorrhoea and irritability
- lid lag can occur in any form of hyperthyroidism, but exophthalmos (protrusion of the eyeballs) is exclusive to Grave's Disease
- investigations: thyroid function test (TFT), thyroid antibodies and thyroid scintiscan (uniform uptake of radioactive iodine, in contrast to a toxic nodule)
- treatment: carbimazole is the most commonly used drug treatment for hyperthyroidism. Some patients may require beta-blockers or radioactive iodine or surgery

Source: Harrison's Principles of Internal Medicine. 16th edition. McGraw-Hill

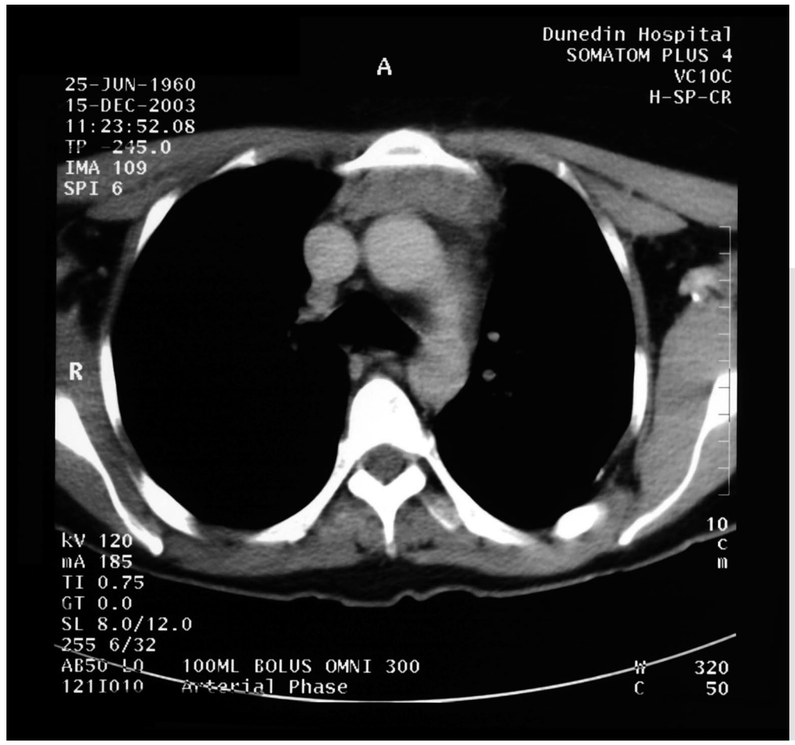

Figure 2.
Contrast-enhanced CT scan of neck and mediastinum indicating hyperthyroidism.

ARTICLE

Talar neck fractures: results and outcomes

Vishal Pai
Fourth Year Medicine
Dunedin School of Medicine
University of Otago

ABSTRACT

Although talar neck fractures are uncommon, they have been associated with high complication rates which can result in permanent disability. The aim of this study was to see whether the type of talar fracture affected the treatment and functional outcome. A retrospective review of 41 patients at Dunedin Hospital with fractured tali was completed. This identified 16 fractures of the neck of the talus (using Hawkins classification) which was a major part of the study. Complications and secondary procedures were reviewed, and radiographic evidence of osteonecrosis and posttraumatic arthritis was evaluated. Although the results showed an association between the type of fracture and the functional outcome, the results were largely inconclusive due to a small sample size and other pitfalls in study design.

INTRODUCTION

The talus forms the ankle joint with the tibia, the subtalar joint with the calcaneus and the midtarsal joint with the navicular bone. Talar fractures are grouped into head, neck, body, lateral and posterior process fractures (Figure 1). The talus has no musculotendinous attachment and 60% of its surface is covered by cartilage, which considerably limits its circulation[2]. This explains the high incidence of avascular necrosis (AVN) following fracture neck of talus.

The Hawkins classification system categorizes talus fractures into groups based on radiographic evidence. This system can be used to predict the outcome and treatment of the fracture (type 1 fractures have the best outcome and type 4 have the worst). The system is described below.

type 1:	undisplaced fracture
type 2:	displaced fracture with dislocated subtalar joint
type 3:	displaced with dislocation of the body of the talus form both the subtalar and ankle joints
type 4:	displaced with dislocation of the body of the talus form both the subtalar and ankle joints as well as dislocation of the talar head

The degree of displacement in talar neck fractures [as suggested by Hawkins classification] is directly proportional to the rate of avascular necrosis[3].

The recommended treatment for fractured neck of the talus[4]: cast treatment for Group I; closed reduction and screw fixation for Group 2; and open reduction and fixation for Group 3 and 4.

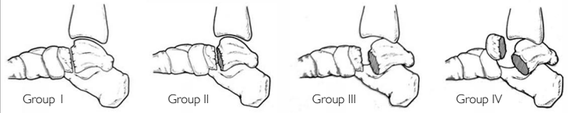

^ **Figure 1: The Hawkins classification system**
Group 1: undisplaced; group 2: displaced with dislocated subtalar joint; group 3: displaced with dislocation form both the subtalar and ankle joints; group 4: type 3, with dislocation of the talar head.

In an extensive study, Hawkins[3] noted avascular necrosis in 0%, 42% and 91% of patients in Group I, II and III respectively. Canale and Kelly[5] later modified this classification scheme, describing a fourth type of talar neck fracture with associated talonavicular dislocation. Studies in the literature to date have demonstrated the occurrence of osteonecrosis in association with as many as 13% of Hawkins I fractures, as many as 50% of Hawkins II fractures, as many as 84% of Hawkins III fractures, and as many as 100% of Hawkins IV fractures[6,7,8].

The main purpose of this study is to evaluate the clinical, radiographic, and functional outcomes of treatment for the fractured neck of talus to see whether the type of talar fracture affected the treatment and functional outcome as described by Hawkins and colleagues.

MATERIALS AND METHODS

A retrospective review was done on forty-one patients with a fracture talus admitted in Dunedin Hospital between 1996 and 2003. Patient information was obtained from their clinical notes, via a questionnaire or a telephone interview. This work was performed under the guidance of Prof. J.C. Theis (Associate Professor of Orthopaedics) after obtaining ethical approval.

These fractures were grouped under different types, depending on the fracture morphology (Table I). The age range of the patients was 15 to 56 with a mean of 38 years, and 66% of them were male. The mechanism of injury was: a motor vehicle accident for seventeen patients; a fall from a height for seventeen; sports-related trauma for six; and an industrial accident for one. Plain radiographs of the foot and ankle were made in all cases. The fractures were classified into groups as described by Hawkins[3] and modified by Canale and Kelly[5].

Although closed, manipulative reduction was attempted at the time of the initial assessment, all fractures subsequently were treated with open

Fracture types	No. of Patients	% of total
neck	16	39
head	4	10
body	4	10
dome	2	5
complex	5	12
lateral/posterior process	2	4
osteochondral fragments	8	20

Table 1: Type of fracture.
Shows the different types of talar fractures and how common they were.

reduction and internal fixation with stainless steel small-fragment and/or mini-fragment implants through anterior or posterior surgical approaches. Table 2 shows that majority of type II and III neck fractures were treated with internal fixation.

The radiographs were made at 6 weeks, 12 weeks, 6 months and annually thereafter.

1. Union was defined as disappearance of the fracture lines

2. AVN was defined as relatively increased density of the talar dome

3. Arthrosis was defined as loss of joint space, osteophytes, or subchondral sclerosis.

In order to evaluate the functional outcome and health status of this group of patients, we administered the Foot Function Questionnaire. Attempts were made to locate all patients but I could not trace three of the sixteen patients with fracture neck of talus. The patients who failed to answer the questionnaire were contacted by telephone and interviewed.

RESULTS

Sixteen talar fractures out of 41 were fractures of the neck of the talus (Hawkins Type I in 6; Type II in 8 and Type III in 2]. In five additional cases there was fracture neck of talus with associated fracture of either body or head or lateral process; this was classified as a complex fracture (Table 1).

All type I fractures were treated in a cast and the average time until full weight bearing was 7.7 weeks. There was one Type I fracture that was comminuted and this was not included in the previous result as it was an outlier and took 12 weeks until the patient could fully weight bear. All eight type 2 fractures were treated by ORIF (Open Reduction Internal Fixation) and took an average of 21.2 weeks until full weight bearing. Type 3 fractures were also treated by ORIF and took an average of 33 weeks until full weight bearing. Anatomic reduction was achieved in fifteen out of sixteen patients.

The functional outcome is an overall indicator of how well the patient has recovered, which takes into account the pain, range of movement (ROM), walking ability on flat ground and on stairs *after* the patient has been treated.

Two patients (number 2 and 3) were lost to follow-up and were not able to be contacted. Of the 13 patients with a complete follow up, there were eight good-excellent results; 3 fair results and two poor results (number 11 and 16).

Out of these 7 patients with AVN, 4 were Hawkins Type II fractures, 2 were Type III fractures, and one was a complex fracture. 5 patients developed malunion, one patient developed non-union, one patient with delayed union, one patient had delayed superficial infection and 8 patients developed arthritis.

DISCUSSION

Historically, "flying accidents" were a common cause, and hence talar fractures were coined the "aviator's astragalus" [9]. However, today these fractures usually occur as a result of motor vehicle accidents or falls from heights, which occurred in 84% of the injuries in this study. A high incidence (67%) of associated injury of both adjacent structures and remote structures in relation to talar neck fractures been reported by Hawkins. The incidence of associated injuries in this series was 56%.

A fractured neck of the talus is uncommon and occurs in 30% of talar fractures[7]. It is second in frequency to chip and avulsion fractures[8]. The incidence in the present series of 41 cases is 39%.

Patient	Type of Fracture	ROM	Pain	Walking	Stairs	Functional outcome	Remarks
1	Type I	Fair	Mild	Good	Good	Good	Quest.
5	Type I	?	?	?	?	?	LFU
6	Type I	Good	None	Good	Good	Good	Records
8	Type I	Normal	Mild	Good	Good	Good	Phone
10	Type I	Poor	Mild	Fair	Fair	Fair	Phone
14	Type I	Normal	None	Normal	Normal	Excellent	Quest.
2	Type II	?	?	?	?	?	LFU
3	Type II	?	?	?	?	?	LFU
4	Type II	Good	Mild	Normal	Normal	Good	Records
15	Type II	Fair	Mild	Good	Good	Good	Quest.
16	Type II	Poor	Extreme	Poor	Poor	Poor	Quest.
11	Type II	Poor	Moderate	Poor	Poor	Poor	Quest.
12	Type II	Fair	Mild	Good	Good	Good	Quest.
13	Type II	Poor	Moderate	Fair	Fair	Fair	Quest.
7	Type III	Fair	Mild	Good	Good	Fair	Records
9	Type III	Fair	Moderate	Good	Good	Good	Phone

Table 3: Clinical Outcome (questionnaire/clinical notes) of fracture neck of talus. Patients were ranked in the type of fracture to demonstrate its possible relationship with the severity and complication of the outcome.

Type of Fracture	Osteoarthritis	AVN	Malunion	Nonunion
Neck: Type I	0% (0)	0% (0)	17% (1)	0% (0)
Neck: Type II	43% (3)	57% (4)	29% (2)	29% (2)
Neck: Type III	50% (1)	100% (2)	50% (1)	0% (0)
Body	20% (1)	0% (0)	0% (0)	0% (0)
Complex	40% (2)	20% (1)	20% (1)	0% (0)

Table 4: Complications of all talar fractures

Hawkins classification[3] for fracture neck talus proved to be very helpful in predicting the long- term outcome. The complication chart (Table 4) agrees with this. Patients with talus fractures of Hawkins Type I and II had considerably better outcomes (with 95% being excellent or good) than individuals suffering dislocated fractures with involvement of the articulating surface. Pajendra[6] claims there were 70% good results in Hawkins Type III and 10% good results in Hawkins Type IV fractures. In a series of 102 cases of fracture neck of talus, Vallier[10] reported a 39% occurrence of avascular necrosis in Type II and 64% in Type IV fractures.

Mild to moderate osteoarthritis of the ankle joint was seen in 5 patients (and severe osteoarthritis in 2 patients (40%), one of whom is waiting for an arthrodesis. Schulz[11] reviewed 80 talar fractures of which 80% reported significant stiffness. In the present series the ankle joint, subtalar joint or both was significantly stiff in 70% of patients.

Despite the small number of patients involved and the use of retrospective data, this study hints that the outcomes were generally predictable by the Hawkins classifications system. However, the results remain largely inconclusive as the procedures were performed by different surgeons with varying experience and a high incidence of patients lost to follow-up. Additionally, documentation regarding post-operative assessment was incomplete. A cohort study with a larger sample size and treatment given by the same doctor would give more conclusive results about functional outcome.

REFERENCES

1. Budiman-Mak E, Conrad KJ, Roach KE
The Foot Function Index: a measure of foot pain and disability
J Clin Epidemiol. 1991; 44: 561-70

2. Mulfinger GL, Trueta J
The blood supply of the talus
J Bone Joint Surg Br. 1970; 52:160-7

3. Hawkins LG
Fractures of the neck of the talus
J Bone Joint Surg Am. 1970; 52: 991-1002

4. Bucholz RW, Heckman
Rockwood and Green's Fracture in Adults
Vol 2. Ed. Lippincott pp. 2091, 2001

5. Canale ST, Kelly FB Jr.
Fractures of the neck of the talus: long-term evaluation of seventy-one cases
J Bone Joint Surg Am. 1978; 60: 143-56

6. Pajenda G, Vecsei V, Reddy B, Heinz T
Treatment of talar neck fractures: clinical results of 50 patients
J Foot Ankle Surg. 2000; 39: 365-75

7. Pennal, GF
Fracture of talus
Clinical orthopaedics. 30; 53-63, 1963

8. Coltart WD
Aviator's astragalus
J Bone Joint Surg 34 B; 545-6, 1952

9. Anderson HG
The medical and surgical aspects of aviation
London: Oxford Univ Press, 1919

10. Vallier HA, Nork SE, Barei DP, Benirschke SK
Talar Neck Fractures: Results and Outcome
J Bone Joint Surg 86A: 1616-1624 2004

11. Schulze W, Richter J, Russe O, Ingelfinger P, Muhr G
Surgical treatment of talus fractures: a retrospective study of 80 cases followed for 1-15 years
Acta Orthop Scand. 73(3): 344-51 2002

Acknowledgement

I am grateful to Associate Professor J C Theis and orthopaedic registrar Dr. Vasu Pai for their help throughout the project.

Correspondence:
Vishal Pai
1 Drummond street
Dunedin
E-mail: vishal21@slingshot.co.nz
Mobile: 021 1898995