

Treatment Options for Patients with Intracranial Melanoma Metastasis

Dr. Ben Harley

1st Year House Officer
Whanganui Hospital
Whanganui

Ben graduated from the University of Auckland. He has a special interest in neurological conditions and their treatment, and completed his 6th year elective working in a neurosurgical department in Kathmandu, Nepal. In his spare time he enjoys trekking in the Waitakere ranges in West Auckland, and was also the executive vice president on the Auckland University Medical Students' Association education committee.

INTRODUCTION

Melanoma is a significant health problem in New Zealand, the rates of which are higher than any other country in the world. European males over the age of 59 are at greatest risk.² Metastasis to the brain has been estimated to occur in 40% or more of cases of advanced melanoma³ and carries a median overall survival ranging from 4 to 5.5 months.¹ This report presents the case of a patient diagnosed with metastatic melanoma and outlines the current treatment options.

CASE REPORT

Mr D is an 83 year old male who presented with a four week history of right-sided weakness and seven day history of "slurred speech". He reported dropping objects from his right hand and gait disturbance, progressively worsening over a four week period. Four months prior, an advanced melanoma (nodular melanoma, Clark's level V, Breslow thickness 4.6 mm, with vertical growth phase with a mitotic rate of 7 mm² and microscopic satellitosis) was excised from his back. A previous Computed Topography (CT) scan of his brain revealed two left hemispheric lesions, thought to be most in-keeping with metastatic melanoma.

His background history includes a stage T1c Gleason score 7 (3+4) adenocarcinoma of the prostate, presenting PSA of 13.8 in 2009. This has been managed with observation and a recent PSA was 20. He also underwent an anterior resection in 2007 for a Duke's B rectal cancer and he did not receive adjuvant therapy. Mr D has gout for which he takes allopurinol. He is a retired office worker and is independent with activities of daily living. He is also a non-smoker and does not drink alcohol.

Examination elicited right-sided foot drop and generalised spasticity on the right hand side. There was 4- weakness on right finger flexion, extension and abduction; sensation was decreased in the same hand. There was 4- weakness of right leg hip extension, foot dorsiflexion and plantar-flexion, and decreased sensation distal to the mid-tibia. Cranial nerve examination was unremarkable, as were cardiovascular, respiratory and abdominal examinations.

CT imaging of the brain revealed expansion of existing lesions and

surrounding oedema and no suspected associated haemorrhage (Fig. 1) when compared with the recent imaging. Blood tests were unremarkable.

Following consultation with the Neurosurgical team it was decided that surgical intervention was not a suitable option. This included a biopsy for histological diagnosis as it was felt that irrespective of diagnosis the treatment options remained the same.

Mr D was reviewed by radiation oncology and initially was referred for stereotactic (i.e. targeted) radiotherapy, which is performed in Dunedin. However in view of the worsening neurological symptoms and performance status Mr D was deemed to be ineligible for this treatment, and after discussion with the patient was instead prescribed a course of whole brain radiotherapy (WBRT).

FOLLOW UP

Following my involvement with Mr D he received 10 treatments of WBRT over 11 days with 6X at a dose of 3 Grays (Gy) per treatment. Mr D had no headaches, nausea or vomiting or worsening neurological symptoms, and no impact on his personality from this treatment. He however did develop bilateral leg oedema, and ultrasound showed an occlusive thrombus in the left posterior tibial vein and a non-occlusive thrombus in the proximal left popliteal vein, which given his poor prognosis was not treated. Following WBRT Mr D was scheduled to be seen for a 6-week follow up in clinic but sadly passed away prior to that.

DISCUSSION

Without histological confirmation it is impossible to determine with absolute certainty that the brain lesions were metastases from melanoma. Mr D has a history of both bowel and prostate cancer. Both of these cancers can metastasise to the brain, although prostate cancer does so exceedingly rarely and the melanoma is the most likely primary site given the history.¹ Management strategies for brain metastases for most patients are similar regardless of the histological identity of the tumour, making a brain biopsy an unnecessary risk to the patient. This explains why Mr D was told the most likely primary site was melanoma without histological confirmation. This discussion will focus on the treatment options currently available to patients with brain metastases.

Dexamethasone is a corticosteroid which reduces cerebral oedema and therefore relieves raised intracranial pressure effects, including weakness, sensory disturbance and slurred speech.⁴ Dexamethasone restricts vasogenic oedema caused by brain tumours through the disruption of the blood-brain barrier.⁵ Inflammatory mediators are suppressed and expression of cell-cell adhesion proteins is increased resulting in symptomatic improvement in 70% of patients.⁵ It is the preferred steroid of choice due to the reduced mineralocorticoid activity which reduces fluid retention, the long half-life decreasing the dosing frequency, and the

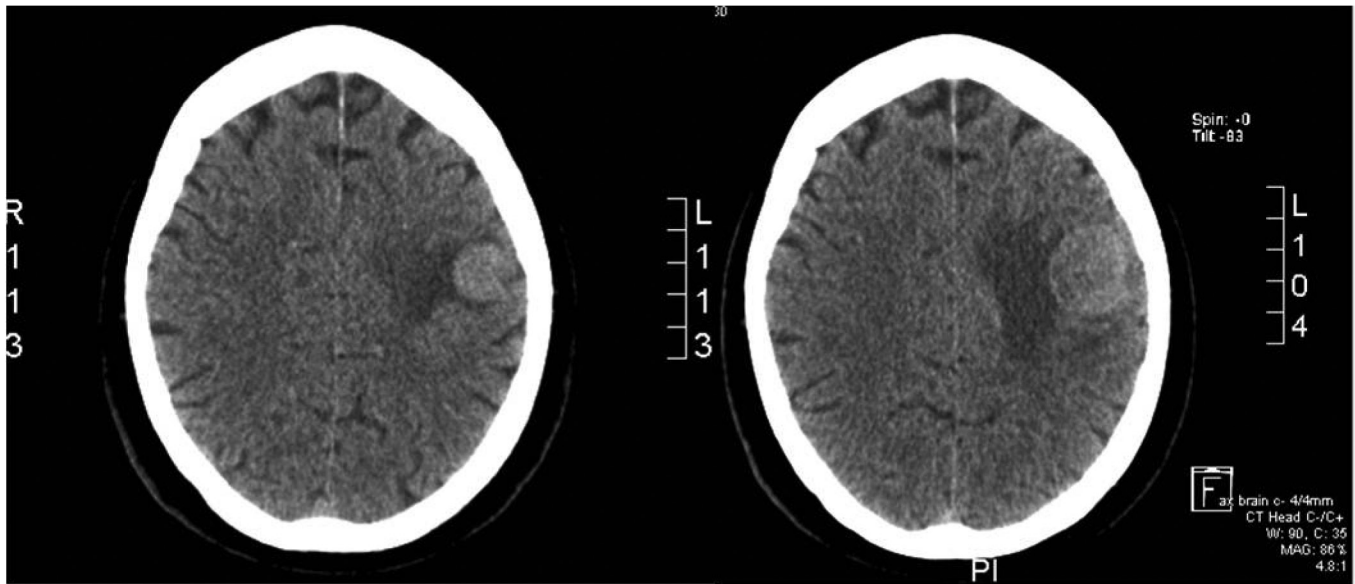


Figure 1. CT head comparing the size of the most lateral and largest of the two metastases performed one month apart. The original scan from the first admission (Left) and the scan from the current admission (Right) are shown.

decreased risk of cognitive impairment.⁵ However side effects do still occur with time in a dose-dependent fashion.

Mr D was at risk of side effects from the dexamethasone, as to control the pressure effects from the tumour oedema he was on 16 mg/day, a higher dose than what patients are usually started on (4-8 mg/day).⁴ Insomnia is a common side effect which can be tempered by administering medications in divided dosages of 8mg in the morning (mane) and 8 mg midday (midi), rather than all given at night (nocte). Following the completion of WBRT Mr D was given a gradually reducing dose of dexamethasone. This was to avoid some of the other side effects that can occur with long term steroid administration. These side effects can include gastrointestinal bleeding, behavioural changes, increased infection risk, weight gain, and fluid retention.⁴ Radiation therapy can obviate the need for long term high dose dexamethasone and also prolong survival, as the survival time with dexamethasone therapy alone can be less than 2 months.¹

Current prognostic guidelines for directing treatment in metastatic melanoma are limited⁶; however radiotherapy is a first-line therapy in the setting of multiple brain metastases.¹ Available treatments include whole brain radiotherapy (WBRT) and stereotactic techniques which is divided into stereotactic radiosurgery (single irradiation) and stereotactic radiotherapy (multiple doses of radiation), the latter of which Mr D was scheduled to receive. Stereotactic radiotherapy, however, is limited by specific criteria including patients with less than four metastases, size of metastases <4cm, good general health status and well controlled systemic disease.⁷ Mr D's worsening clinical symptoms would likely have been what excluded him from receiving the treatment, though the exact size of the lesions was not available to the author and may also have played a role. While stereotactic techniques allow a more concentrated dose of radiation to be delivered to diseased regions of the brain,⁶ WBRT can irradiate micro-metastases that are not able to be visualised on brain scans, at the cost of increased damage to surrounding normal brain tissue.³ Balancing these pros and cons is a critical part of developing an effective treatment plan.

The key comparison in Mr D's case was stereotactic radiotherapy versus WBRT – yet randomised controlled trials (RCTs) comparing these techniques has yet to be performed. There is however a wealth of information on single dose radiosurgery versus WBRT to assist treatment decisions. The latest evidence suggests that there is no overall survival benefit when stereotactic radiosurgery is compared with WBRT.⁹ Furthermore, numerous RCTs have compared different fractionation regimes for WBRT, but there is no evidence that a particular regime offers superior survival, neurological function or symptom benefit compared to the standard 10

dose fractionation regime Mr D received.⁶

Common side effects of radiotherapy can include post-treatment fatigue and cognitive decline,⁸ and while Mr D did not experience these, the deep vein thromboses (DVTs) Mr D developed are a potentially life threatening complication. As demonstrated in this case, the rationale for WBRT was to palliate symptoms. The median survival time following WBRT is 14 weeks⁹ however, Mr D survived less than 4 weeks. The data in the literature is limited and further research is required to establish if WBRT provided a survival benefit over supportive therapy alone.⁶ Apart from radiological treatments, drug therapies are also available as part of effective treatment for melanoma brain metastasis.

A recent review by Nicholas et al. reports that treatment for metastatic melanoma, particularly drug therapy, lags behind advances made in other conditions due to the historical exclusion of metastatic melanoma from clinical trials.¹ Recently however, chemotherapy drugs, such as the alkylating agent temozolomide, when paired with WBRT have been shown to improve tumour regression response rates in metastatic tumours, with no survival benefit.¹⁰ Targeted molecular therapy is another option using drugs such as ipilimumab, a novel immune therapy drug,¹ and vemurafenib, which blocks the MAP kinase pathway.¹ Currently none of these drugs are funded for public use, although are available for patients who seek treatment privately. Vemurafenib is available through clinical trials, though there is no guarantee to the patient that they would receive the drug rather than a placebo.

Exploring on-going clinical trials is a critical step in treating patients with metastatic melanoma as is discussing the role and service provided by the hospice team, as the prognosis for this condition is poor overall. While it is clear that a variety of treatments need to be considered once melanoma brain metastasis has occurred, the most important lesson we can learn from the case of Mr D is the importance of prevention – educating patients about sun awareness and regular mole checks to catch melanoma before metastasis occurs.

REFERENCES

1. Nicholas S, Mathios D, Jackson C, Lim M. **Metastatic melanoma to the brain: Surgery and radiation is still the standard of care.** *Curr Treat Options Oncol.* 2013 Jun;14(2):264-79.

2. Liang JJ, Robinson E, Martin RC.
Cutaneous melanoma in New Zealand: 2000-2004.
ANZ J Surg. 2010 May;80(5):312-6.
3. Klein A, Sagi-Assif O, Izraely S, Meshel T, Pasmanik-Chor M, Nahmias C, et al.
The metastatic microenvironment: Brain-derived soluble factors alter the malignant phenotype of cutaneous and brain-metastasizing melanoma cells.
Int J Cancer. 2012 Dec 1;131(11):2509-18.
4. Ryken TC, McDermott M, Robinson PD, Ammirati M, Andrews DW, Asher AL, et al.
The role of steroids in the management of brain metastases: a systematic review and evidence-based clinical practice guideline.
J Neurooncol. 2010 Jan;96(1):103-14.
5. Dietrich J, Rao K, Pastorino S, Kesari S.
Corticosteroids in brain cancer patients: Benefits and pitfalls.
Expert Rev of Clin Pharmacol. 2011 Mar;4(2):233-42.
6. Tsao MN, Lloyd N, Wong RK, Chow E, Rakovitch E, Laperriere N, et al.
Whole brain radiotherapy for the treatment of newly diagnosed multiple brain metastases.
Cochrane database Syst Rev. 2012;4:CD003869.
7. Levy A, Saiag P, Chargari C, Assouline A.
Focal 3D conformal high-dose hypofractionated radiotherapy for brain metastases.
Melanoma Res. 2012 Oct;22(5):406-9.
8. Nieder C, Marienhagen K, Geinitz H, Grosu AL.
Can current prognostic scores reliably guide treatment decisions in patients with brain metastases from malignant melanoma?
J Cancer Res Ther. 2011 Jan-Mar;7(1):47-51.
9. Murrell J, Board R.
The use of systemic therapies for the treatment of brain metastases in metastatic melanoma: Opportunities and unanswered questions.
Cancer Treat Rev. 2013 Dec;39(8):833-8.
10. Stewart JG, Sawrie SM, Bag A, Han X, Fiveash JB.
Management of brain metastases.
Curr Treat Options Neurol. 2010 Jul;12(4):334-46.
-

