

Heart block simplified

Dr. Mohsin A Hussain

Cardiology Registrar
London
United Kingdom

Dr Mohsin A Hussain is a cardiology registrar working in London, UK. He has a passion for teaching and explaining medical concepts which, with a bit of time and effort, can be easy to understand. The following heart block article demonstrates this and he looks forward to any feedback readers may have.

The aim of this section is to remind the reader to be aware of the different types of heart block and understand key ECG features, thereby assisting in diagnosis. The aetiology or management of the heart block will not be discussed.

FIRST DEGREE HEART BLOCK

First degree heart block is simply a fixed PR interval greater than the upper limit of normal. A normal PR interval is 0.12 – 0.20 seconds; therefore, first degree heart block is a fixed PR interval greater than 0.2 seconds.

Each small square on an ECG represents 0.04 seconds. Therefore, a normal PR interval is between 3-5 squares.

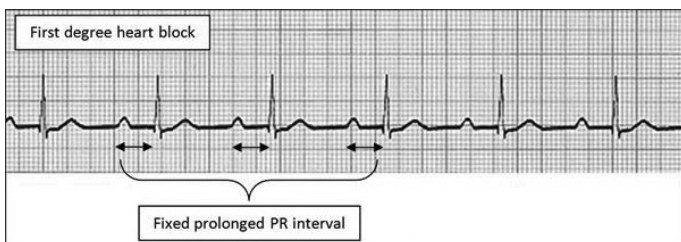


Figure 1 illustrates first degree heart block, where the PR interval is greater than the upper limit of normal. The arrows also show the PR interval remains constant.

SECOND DEGREE HEART BLOCK

Type I (also known as Mobitz I or Wenckebach)

Second degree heart block Type I is represented by a PR interval that progressively increases with every beat. This is followed by a dropped QRS complex, after which the PR interval resets itself and gradually starts to lengthen again. The cycle repeats.

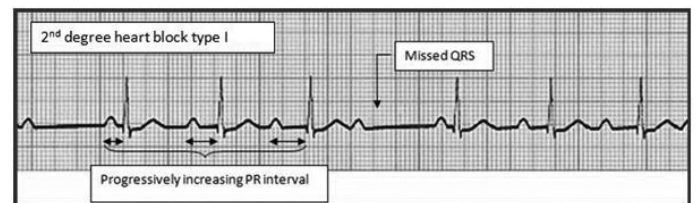


Figure 2 shows a progressively increasing PR interval in second degree heart block Type I. Following the dropped QRS complex, the PR interval returns to its shortest before gradually increasing again. This cycle then repeats itself.

Type II (also known as Mobitz II)

PR length prolongation does not occur in this form of heart block. Instead, P waves fail to conduct to the ventricles. Therefore, every so often—in a random manner—a QRS complex fails to follow a P wave. This is outlined in Figure 3.

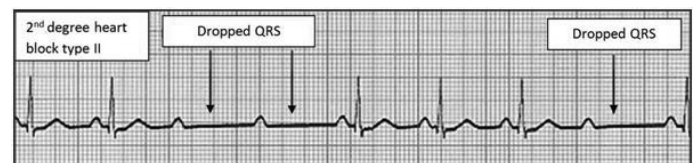


Figure 3 Mobitz II heart block.

Another form of second degree heart block Type II is when there are a fixed number of P waves prior to every QRS complex. For example, two P waves may be present prior to every QRS complex (2:1 block).

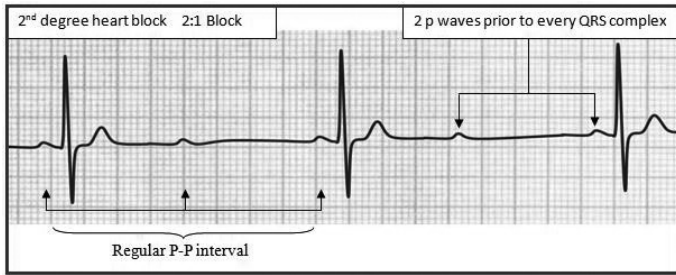


Figure 4 shows an example of second degree heart block Type II, in which there are 2 P waves prior to every QRS complex. This pattern repeats itself, and is also known as a 2:1 heart block. Similarly, if there are 3 P waves prior to every QRS complex, it is known as 3:1 block.

Complete heart block (also known as third degree heart block)

In a normal heart, the SA node is the intrinsic pacemaker and leads to activation of the AV node in an organised fashion.

Complete heart block is a condition whereby the SA node in the atrium does not lead to coordinated ventricular activity. Instead, the atria and ventricles contract independent of each other at different rates (Figure 5).

This manifests itself on an ECG as an absence of a relationship between the P waves (atrial activity) and the QRS complexes (ventricular activity). Both the P-P interval (atrial rate) and R-R interval (ventricular activity) are constant. The AV node is normally stimulated following SA node activation, but in complete heart block, there are no impulses from the SA node propagating through to the AV node. Therefore, a new, slower rhythm kicks in. This rhythm is sometimes referred to as a nodal, junctional, or an escape rhythm.

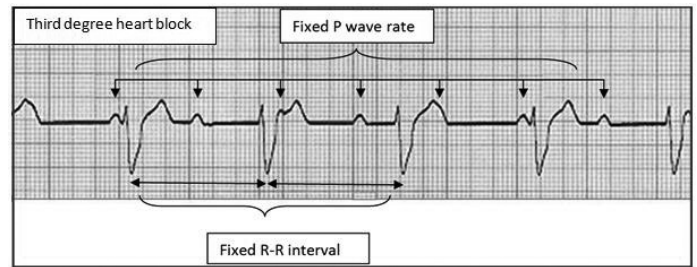


Figure 5 illustrates third degree heart block. There is no relationship present between the P waves (atrial activity) and the QRS complexes (ventricular activity). Instead, both rhythms coexist each at a different, but regular, rate. The atrial rate tends to be faster than the QRS rate. The QRS complexes present in the example are broad. They are therefore likely to originate from lower down in the bundle of His.

This slower rhythm can originate from high up in the bundle of His or AV node and therefore be narrow on the ECG (normal QRS duration). If, however, it originates from lower down in the bundle of His, then it can lead to broader QRS complexes.

WANT TO BE PART OF THE TEAM THAT PRODUCES A JOURNAL FROM START TO FINISH?

As a member of the NZMSJ Executive you will gain valuable skills in editing and reviewing articles. And it looks great on your CV! We have positions open in all aspects of the running of the Journal. This includes:

- Editing and reviewing articles
- Editing and reviewing book reviews
- Design of the Journal
- Managing the finances of the Journal
- Liaising with sponsors for the Journal

You will be well-supported by a fantastic team, and the time commitment is minimal.

For more information:

Visit our website: www.otago.ac.nz/nzmsj

Email us: nzmsj@otago.ac.nz

NZMSJ

New Zealand Medical Student Journal

Te Hautaka o ngaa Akongaa Rongoaa

